

# Radiation therapy for brain cancer: Aiming more to shoot less

Quest for a Cure

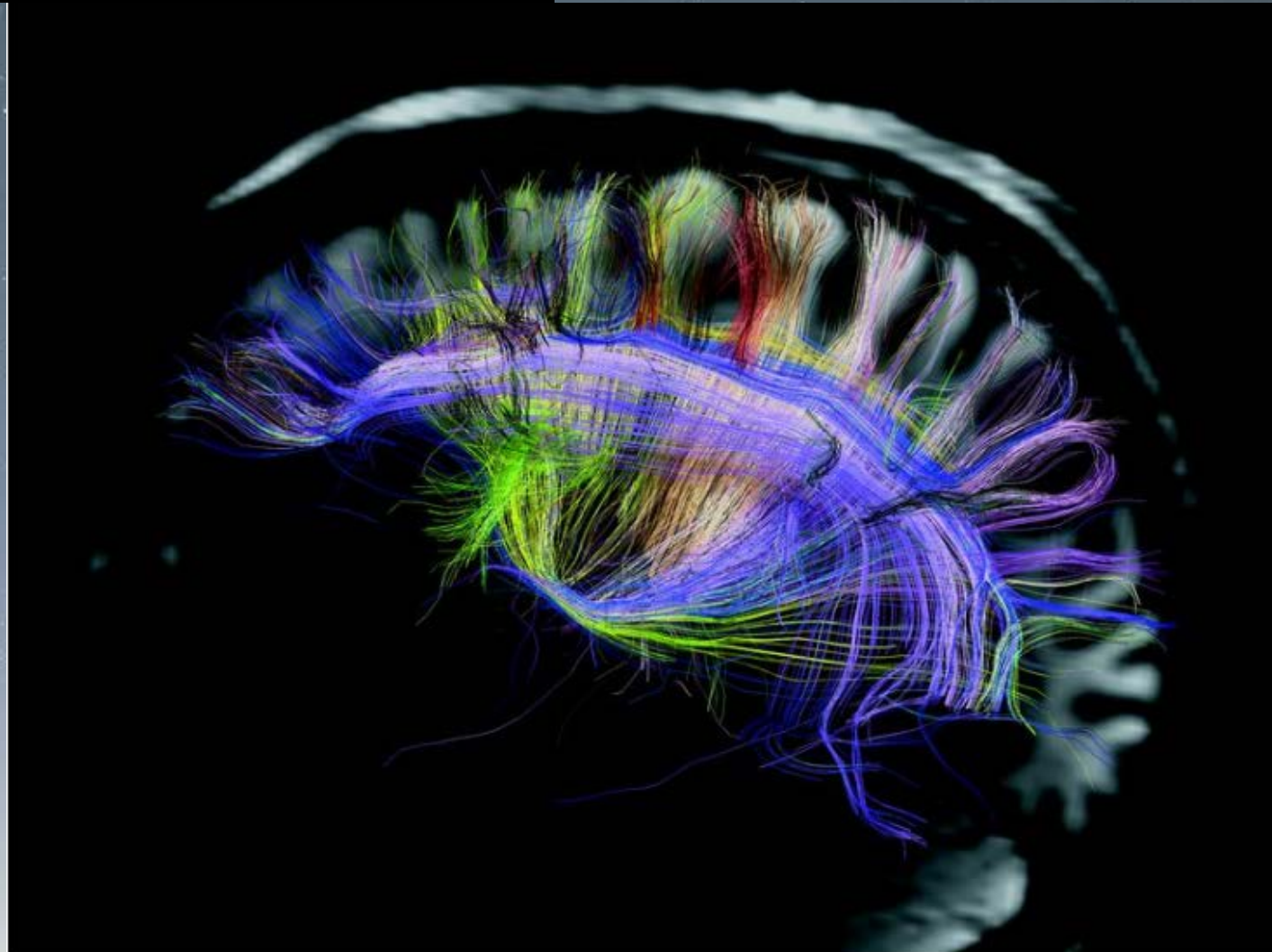
★ Starlight Lecture ★

Christina Speirs, MD, PhD

Cancer Center of Hawaii

Radiation Oncology

May 27, 2021



(Martinos Center For Biomedical Imaging, Massachusetts General Hospital)

# This presentation discusses radiation therapy for brain cancer



Adults



Children

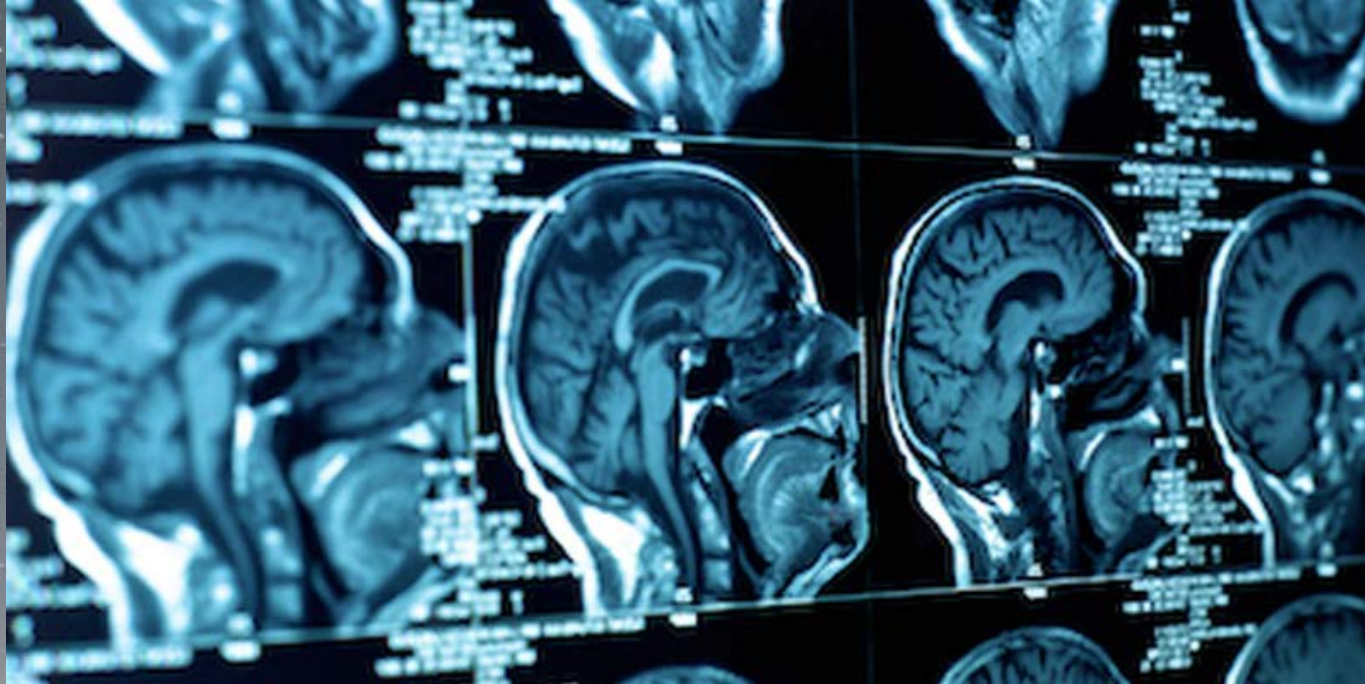

Targeting treatment



Screening symptoms

# Case study: Weakness and disorientation while on vacation



44 year old man seeks medical attention for sudden symptoms



Beau Biden

# Brain cancers can be metastatic or primary

## metastatic vs primary

### BRAIN CANCER

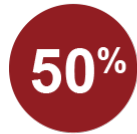**Metastatic:** Cancer spread from another site

**Primary:** Cancer that starts in the brain

#### INCIDENCE



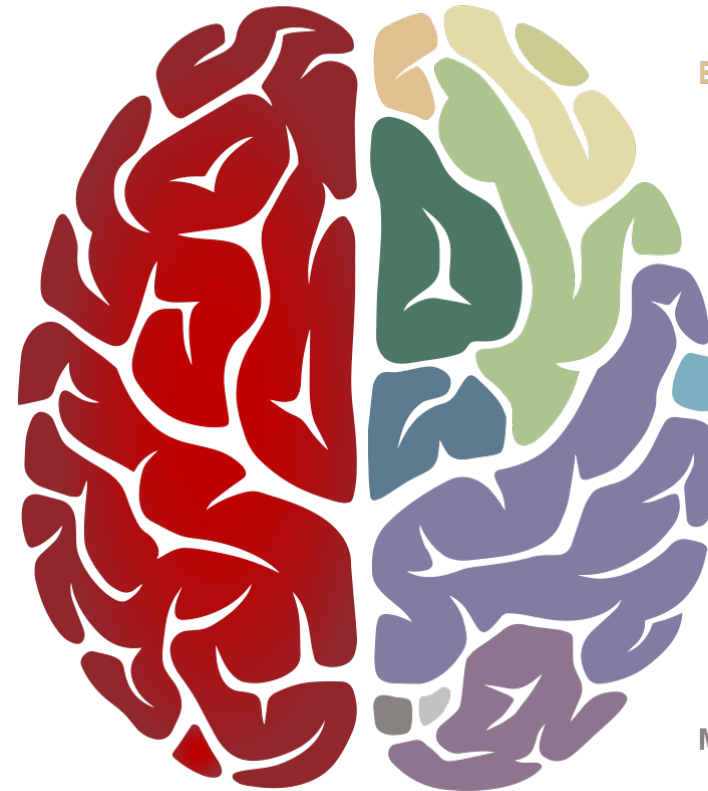Higher than any primary brain cancer



Accounts for half of all CNS tumors



Lung and breast cancer are the most frequent metastasis origin



Ependymomas

Astrocytomas

Lymphoma

**Glioblastoma**

**All Other**

Oligodendrogliomas

Pituitary

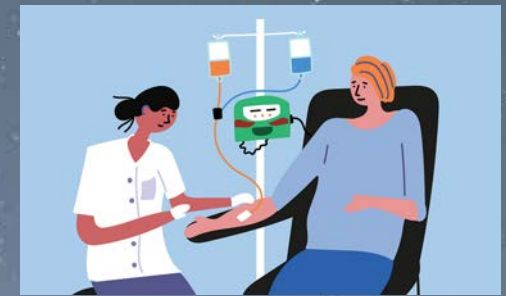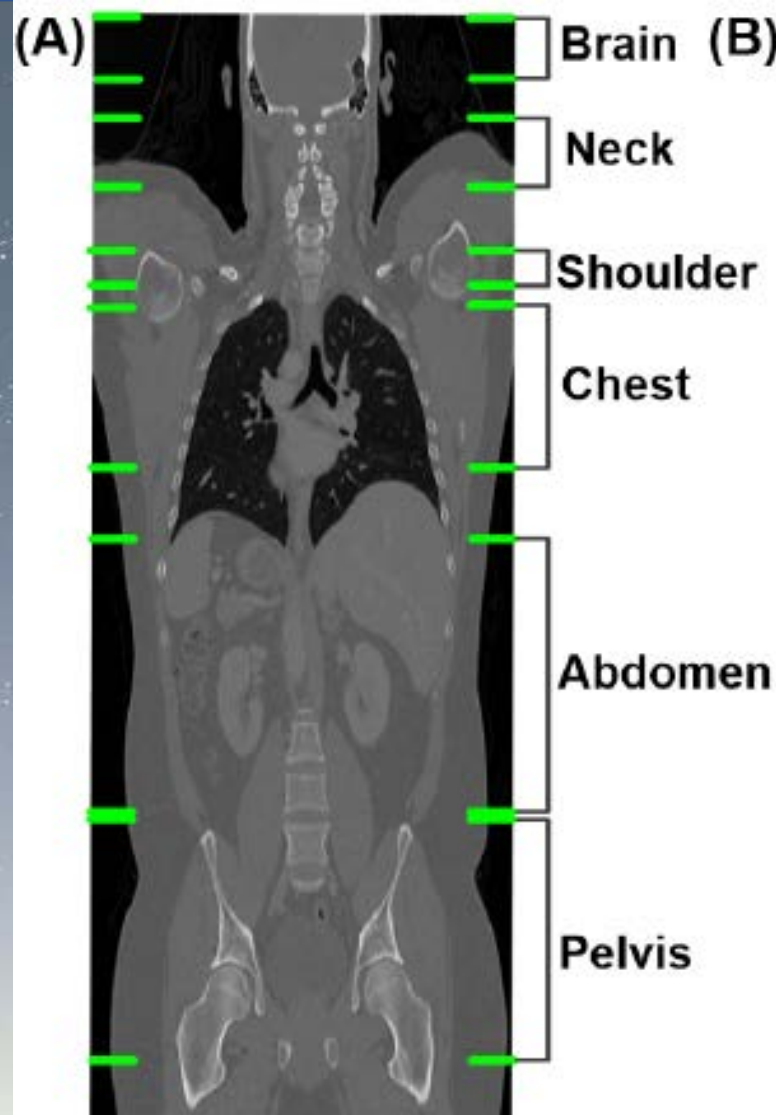
**Meningioma**

Nerve Sheath

Craniopharyngioma

Medulloblastoma

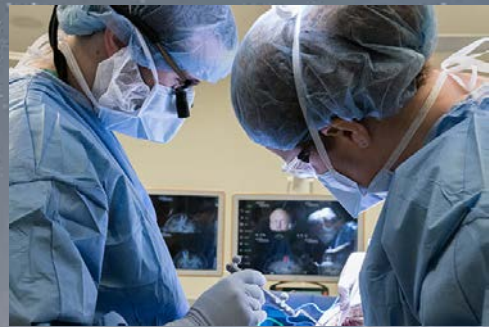# For metastatic brain tumors, you must identify the original cancer site for effective treatment



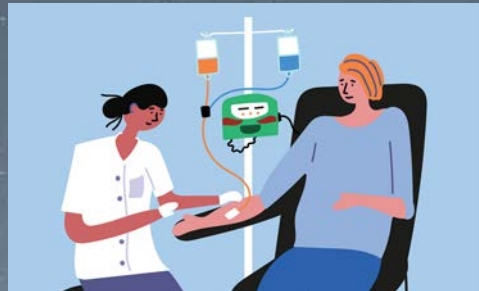Systemic Therapy



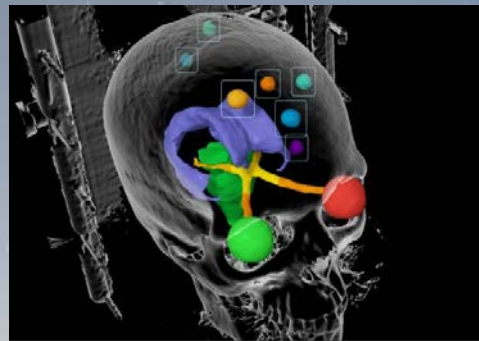
# For metastatic brain tumors, treating the brain tumor can be done using multiple approaches



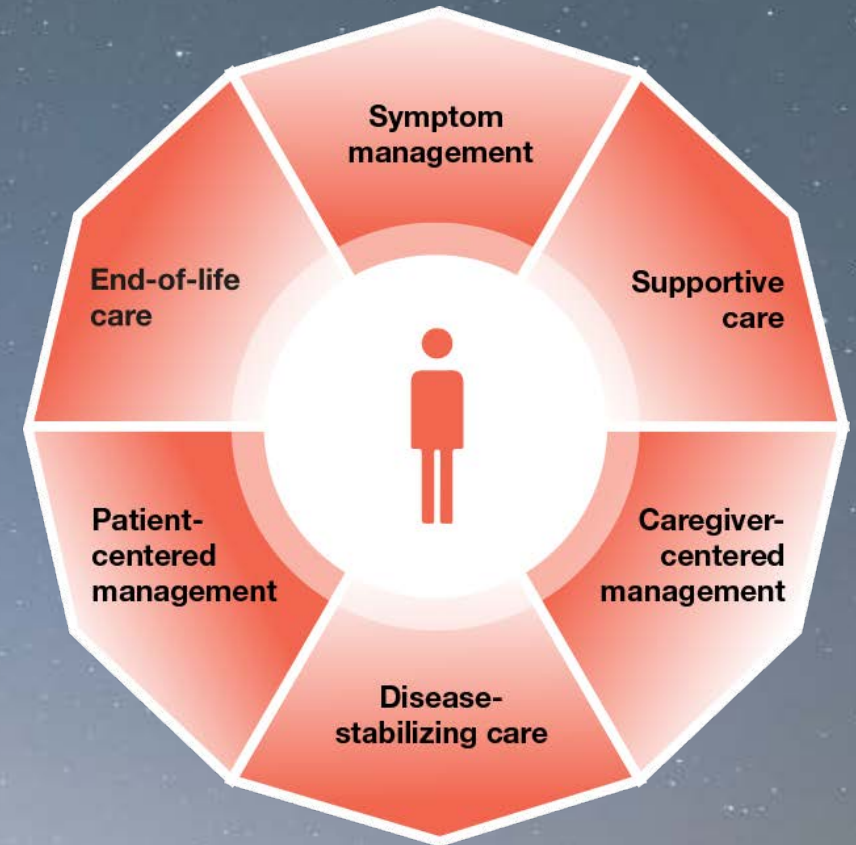
**Surgery\* (Dr. Noh)**



**Systemic Therapy**

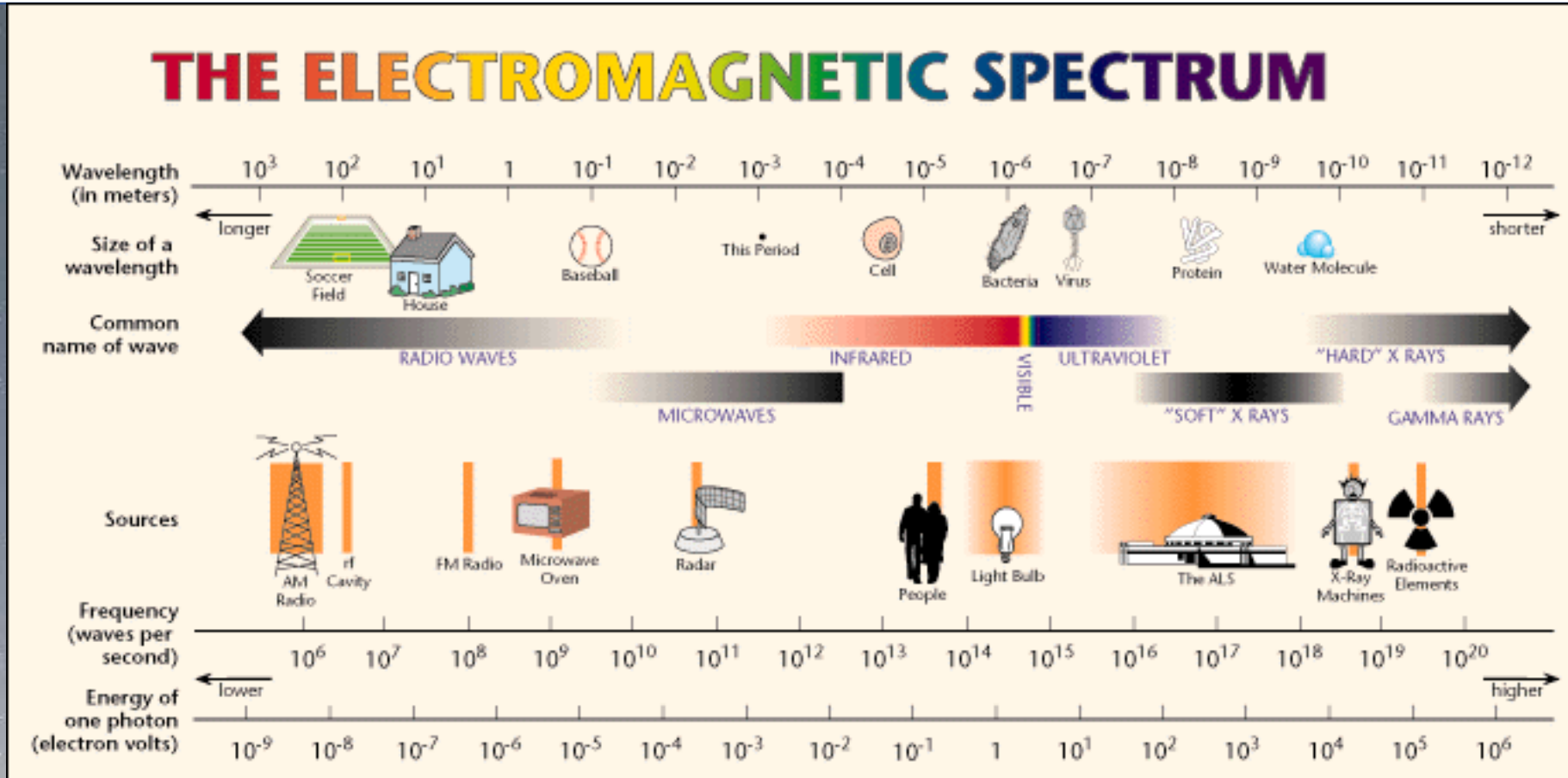


**Radiation Therapy**

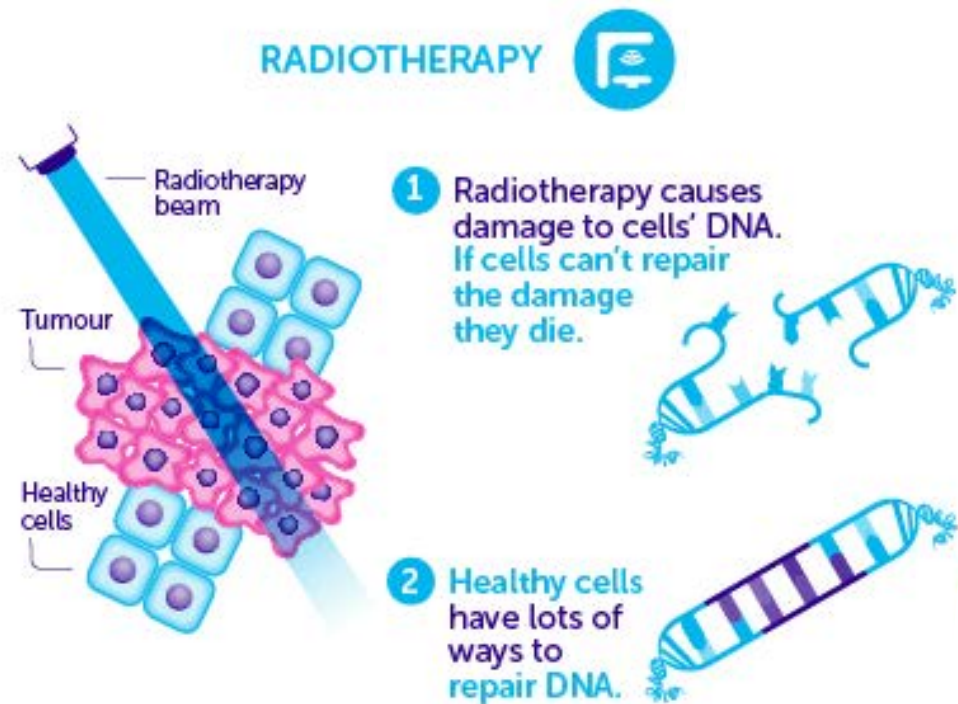


**Supportive Care**

# Radiation is a form of energy

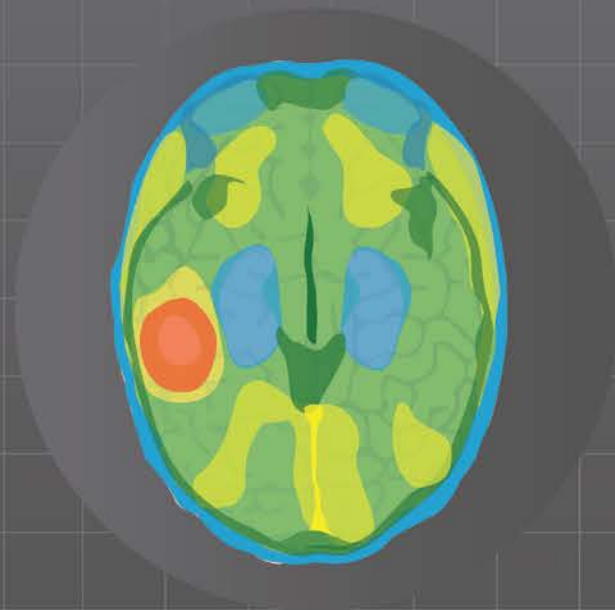


# Radiation therapy uses high energy particles to damage DNA in sensitized cancer cells

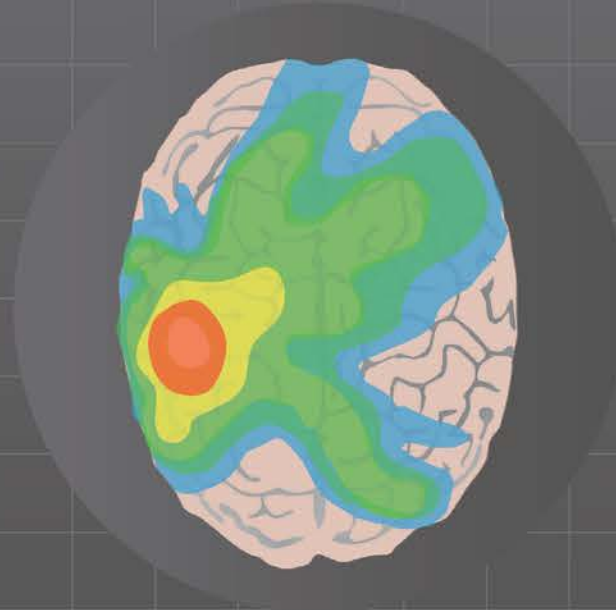


For metastatic brain tumors, brain radiation can be more or less targeted, depending on where the disease is

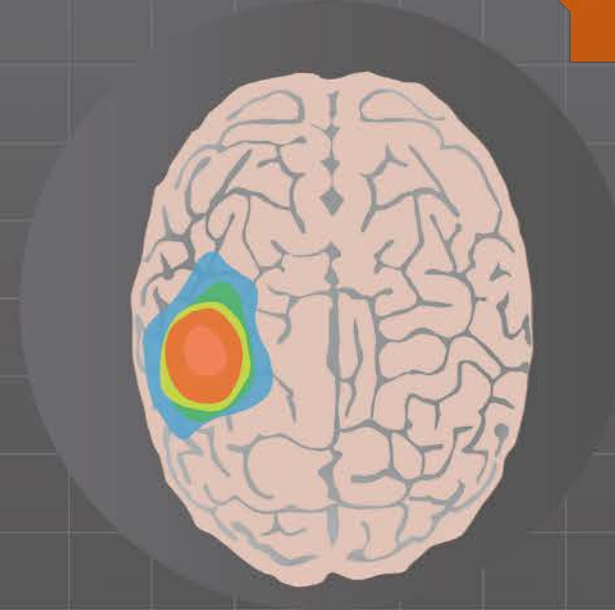
## Different Types of Brain Radiation



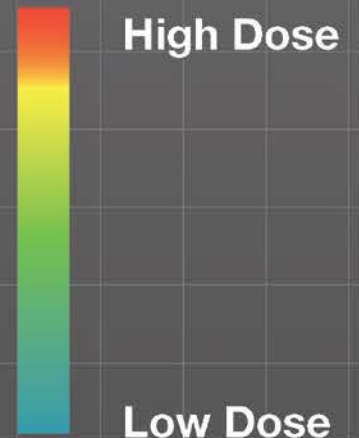
Whole Brain



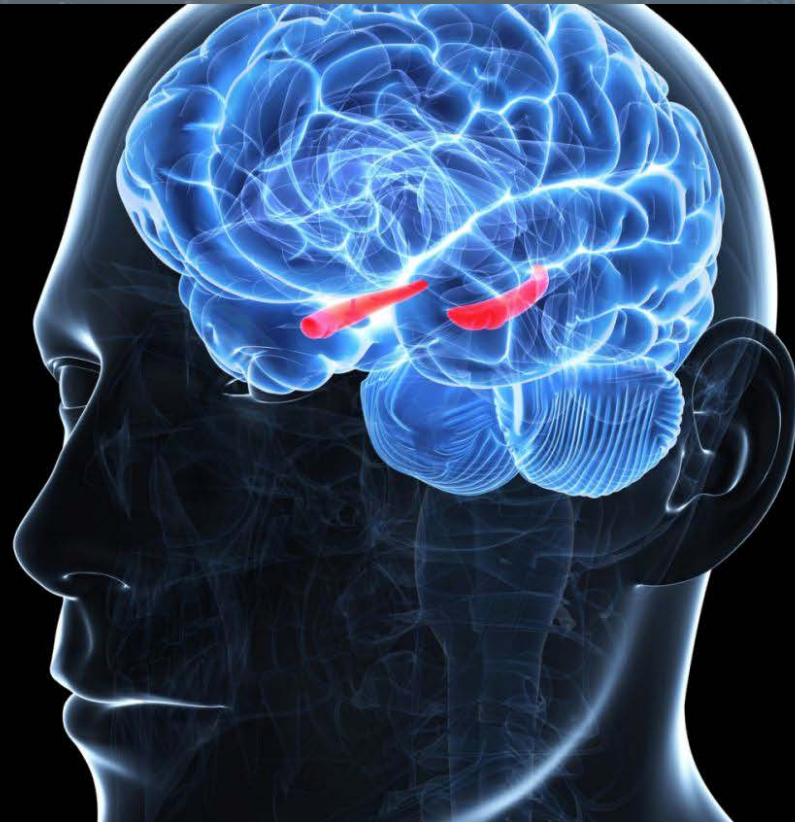Traditional



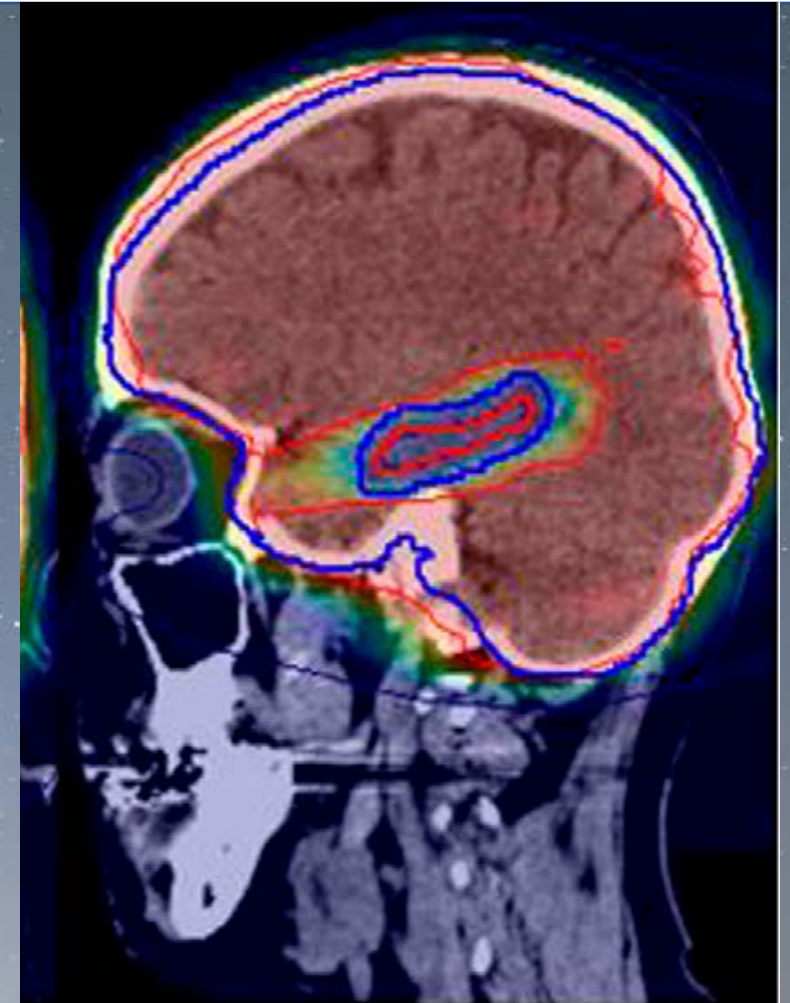
Stereotactic  
Radiosurgery



Even when the whole brain must be treated, targeting can be done with sparing of the hippocampus, our memory center

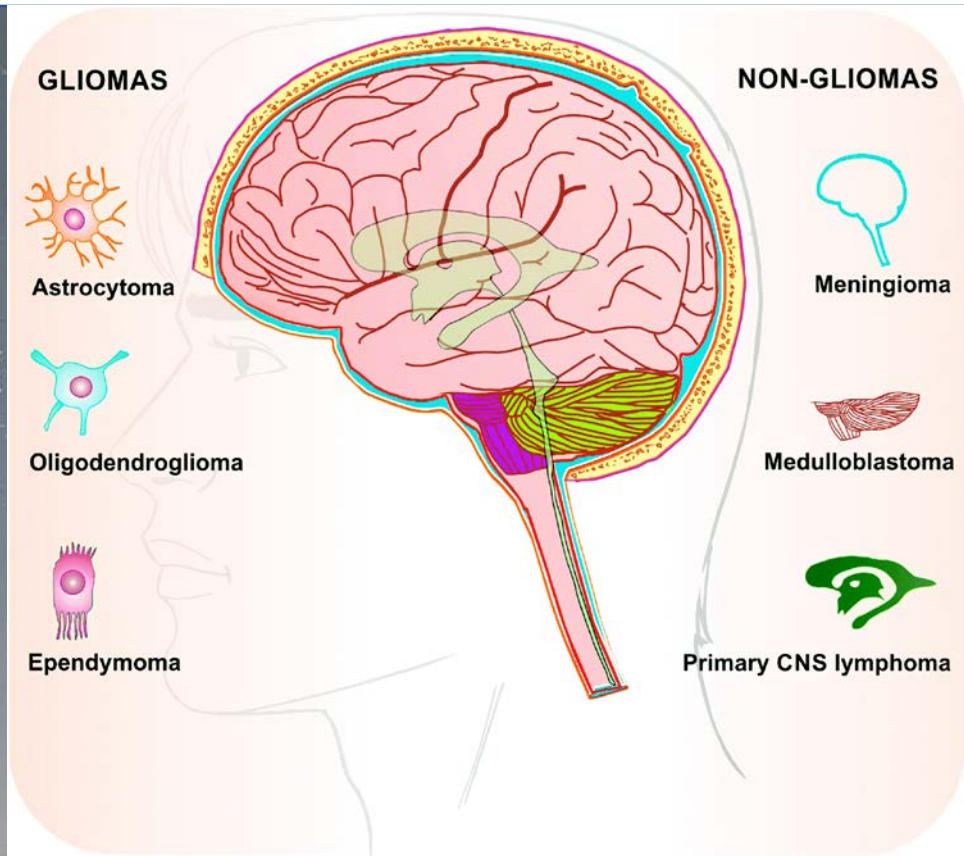


Hippocampus  
(single)  
Hippocampi  
(paired)

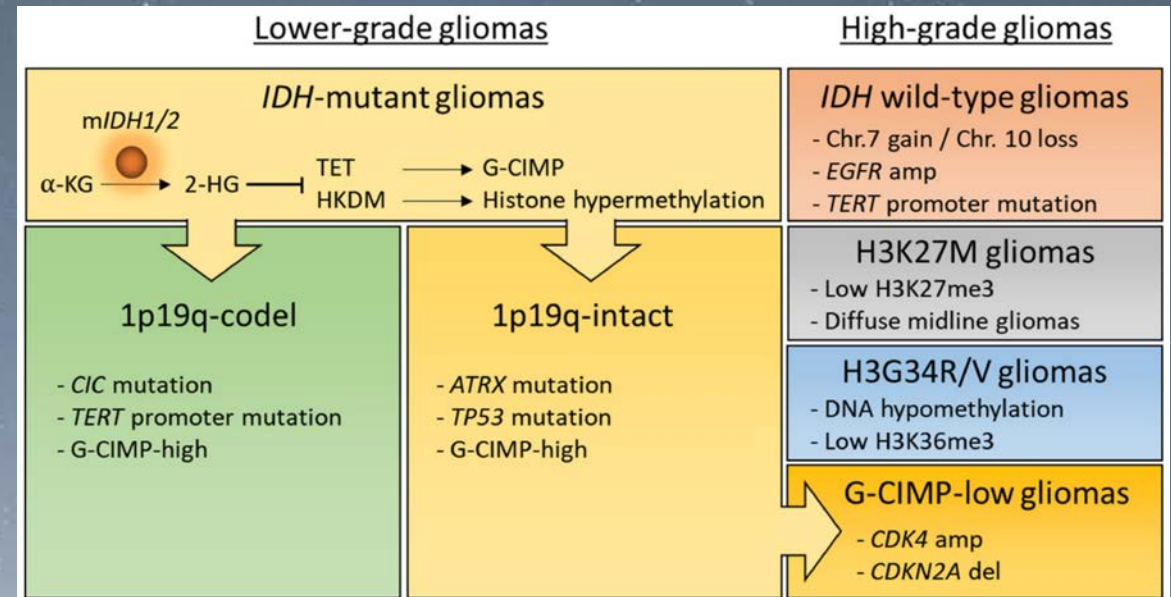


Hippocampal sparing Whole Brain  
Radiation Therapy

# For primary brain tumors, tissue and gene analysis is critical to determining the best, safest treatment

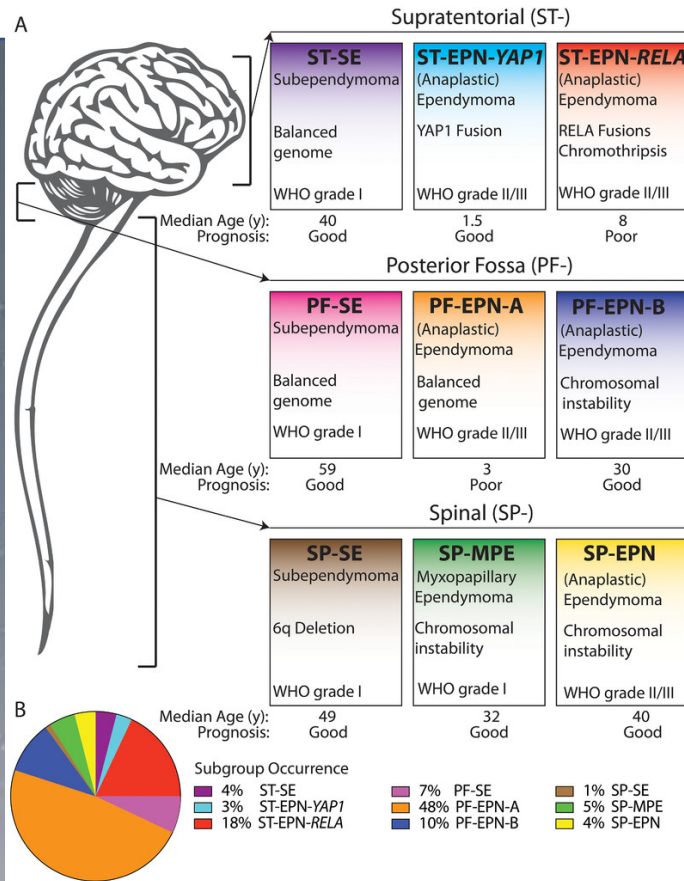


Tissue subtype: Where did it arise?

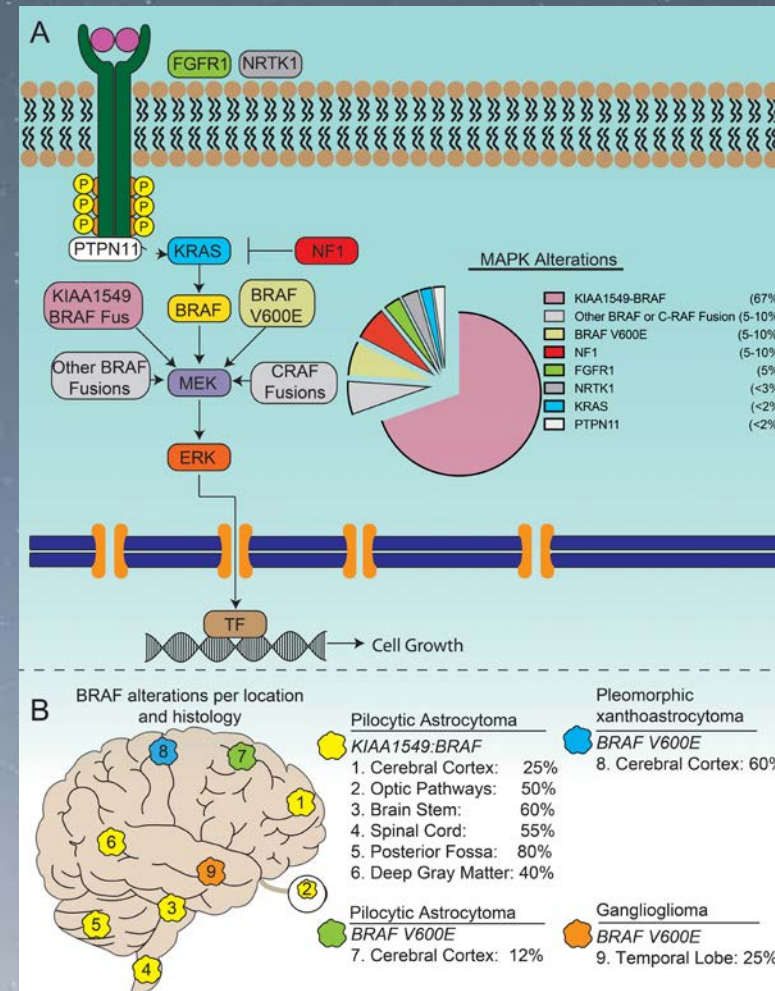


Genetic changes: What drives its growth?

# Children/young adults have very different brain cancers than adults do, but the approach is the same



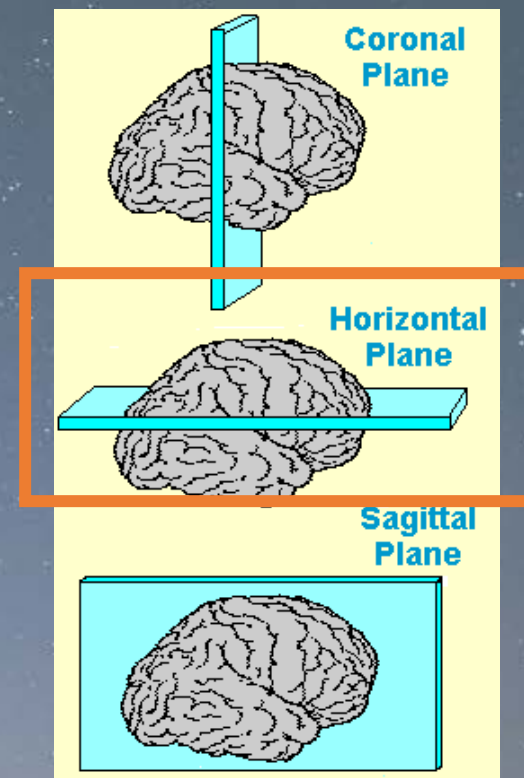
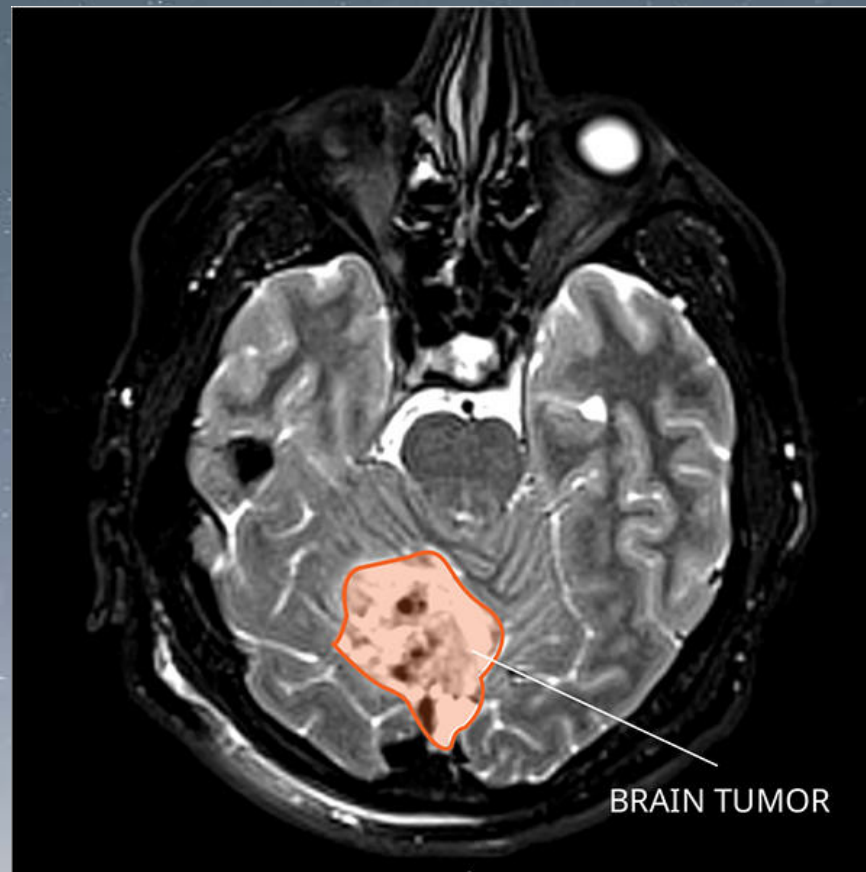Tissue subtype: Where did it arise?



Genetic changes: What drives its growth?

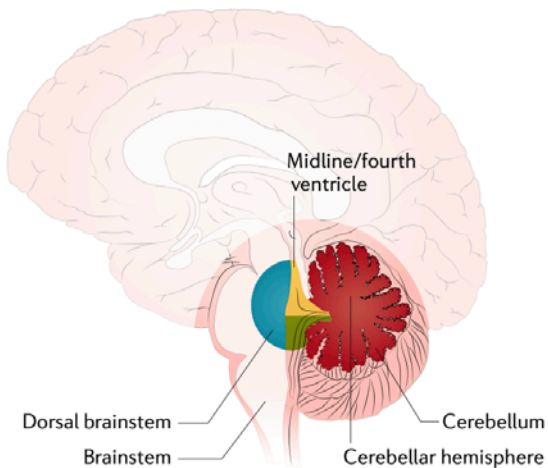
# Case study: Morning headaches, vomiting, and imbalance

13 year old boy with progressive symptoms over 3 weeks is brought to his doctor

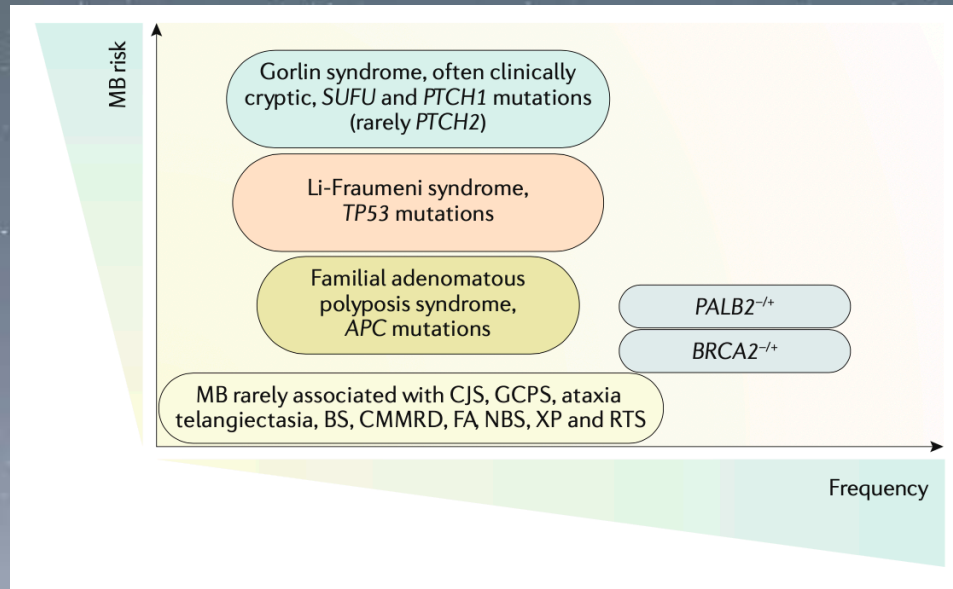


Brain MRI (*Horizontal section*)

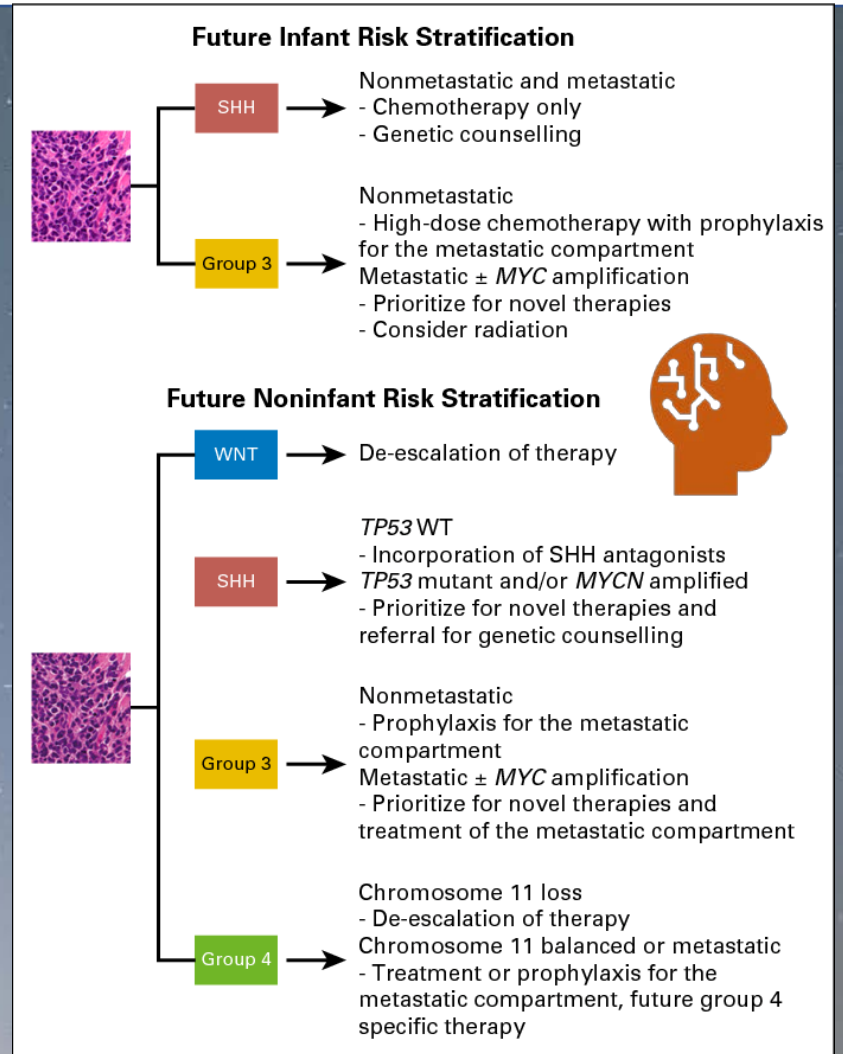
# Medulloblastoma is a cancer that arises from the cerebellum and can spread to the spinal cord



**Fig. 1 | Location of MB.** Sagittal section of the cerebellum and brainstem, with common diagnostic locations of medulloblastoma (MB) indicated on the basis of MRI. MB locations have been colour-coded according to prominent diagnostic locations observed for individual consensus subgroups: WNT (blue); SHH (red); Group 3 (yellow); Group 4 (green).

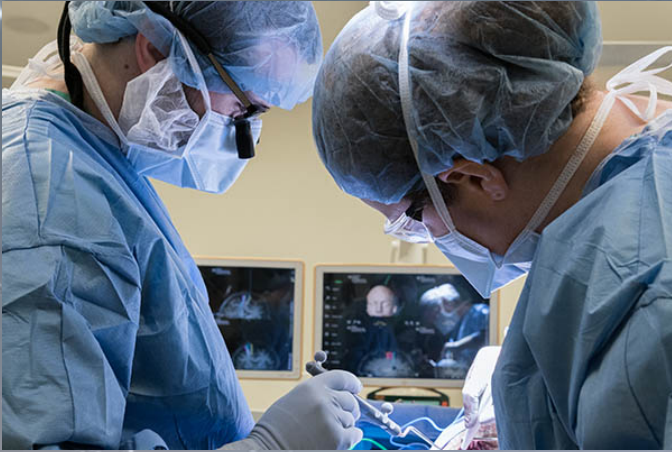

## Genetic predisposition

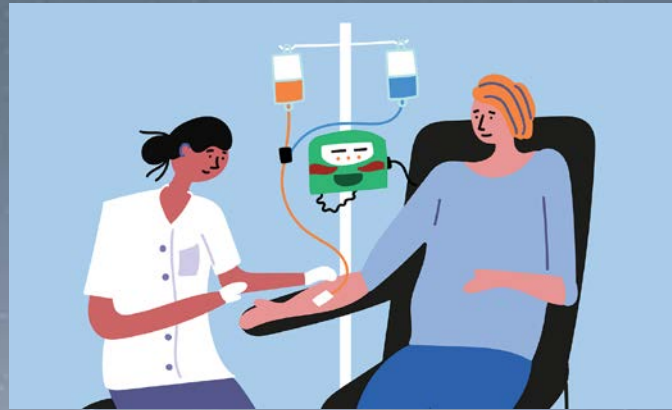


**Fig 4.** Proposed future molecular risk stratification for both infant and noninfant medulloblastoma. SHH, sonic hedgehog; WNT, wingless.

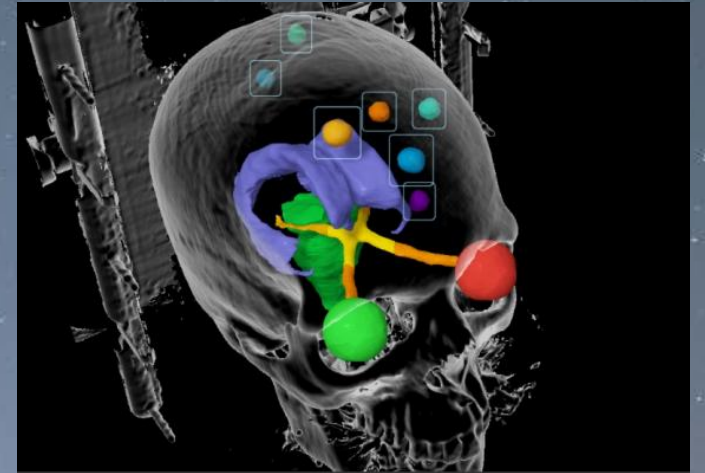
# Medulloblastoma is treated with surgery, chemotherapy, and radiation



**Surgery**

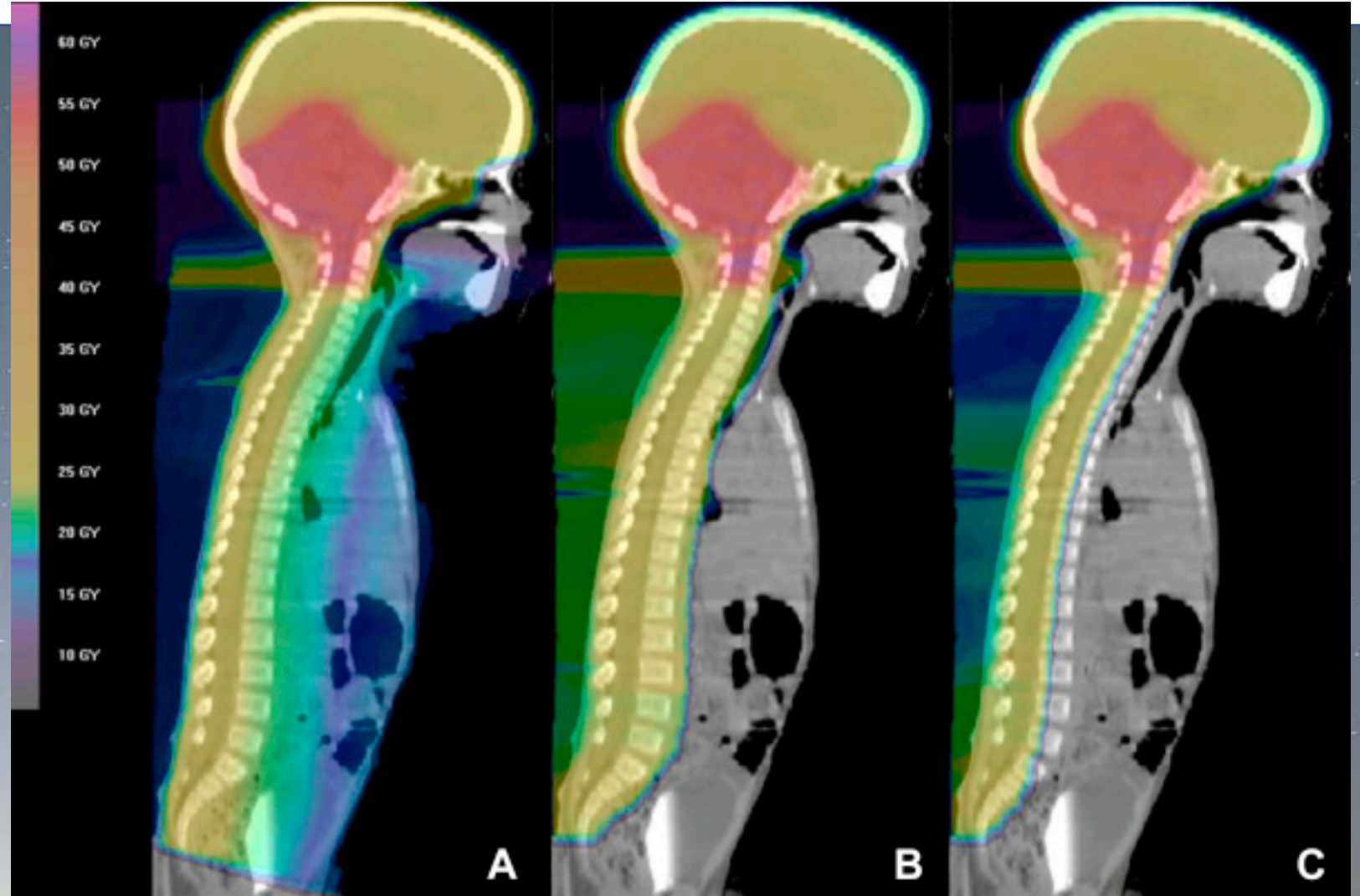
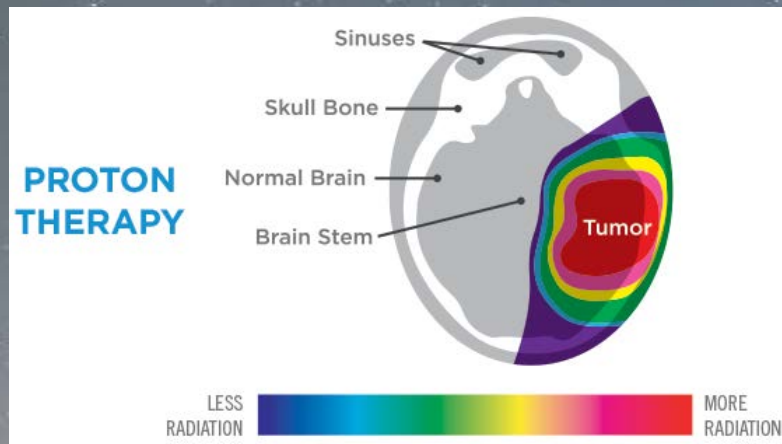


**Systemic Therapy**



**Radiation Therapy**

# Medulloblastoma radiation is directed to the brain and spinal cord and can be targeted with proton therapy

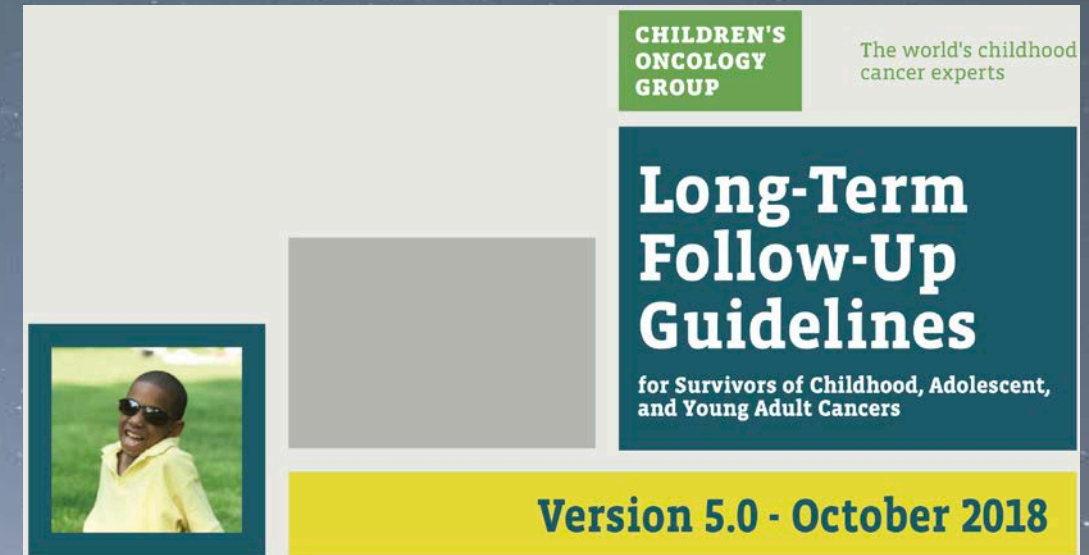
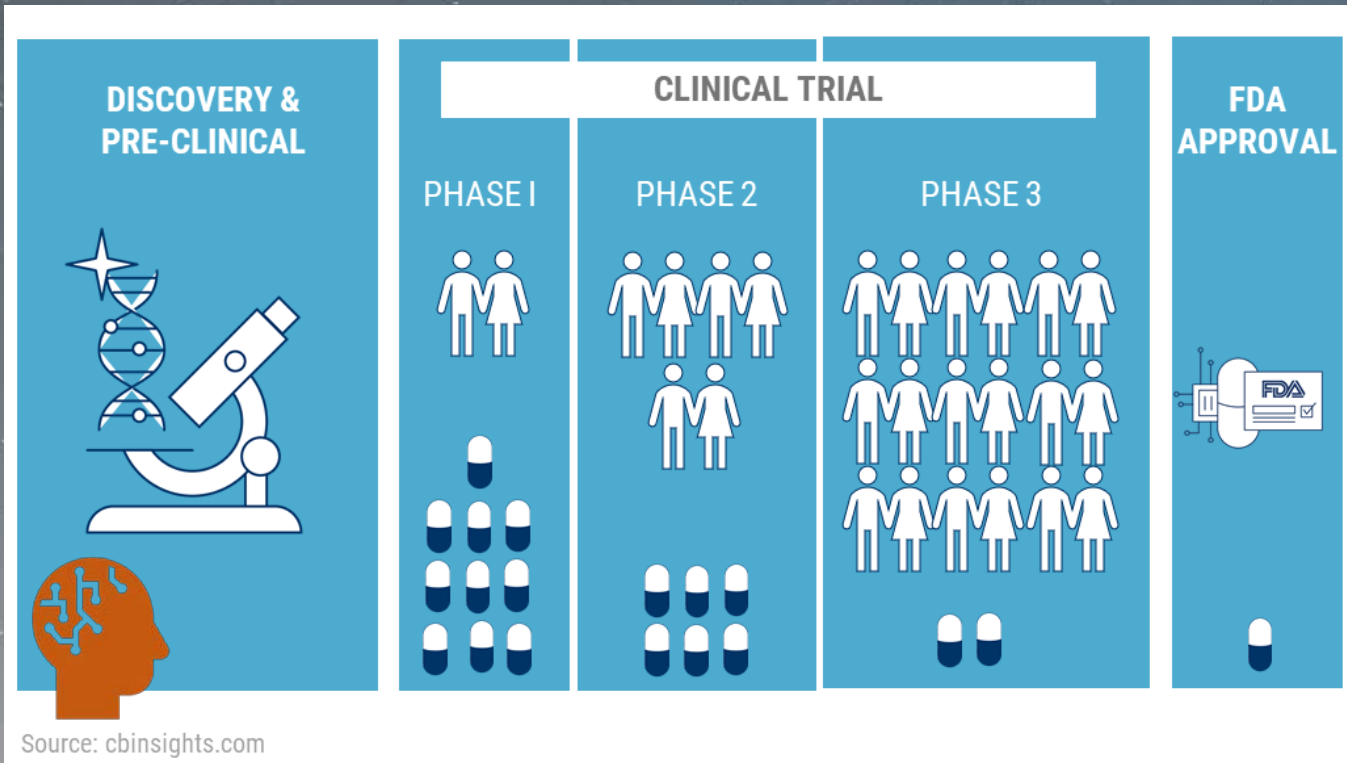


Standard planning

Proton therapy

Proton (sparing vertebrae)

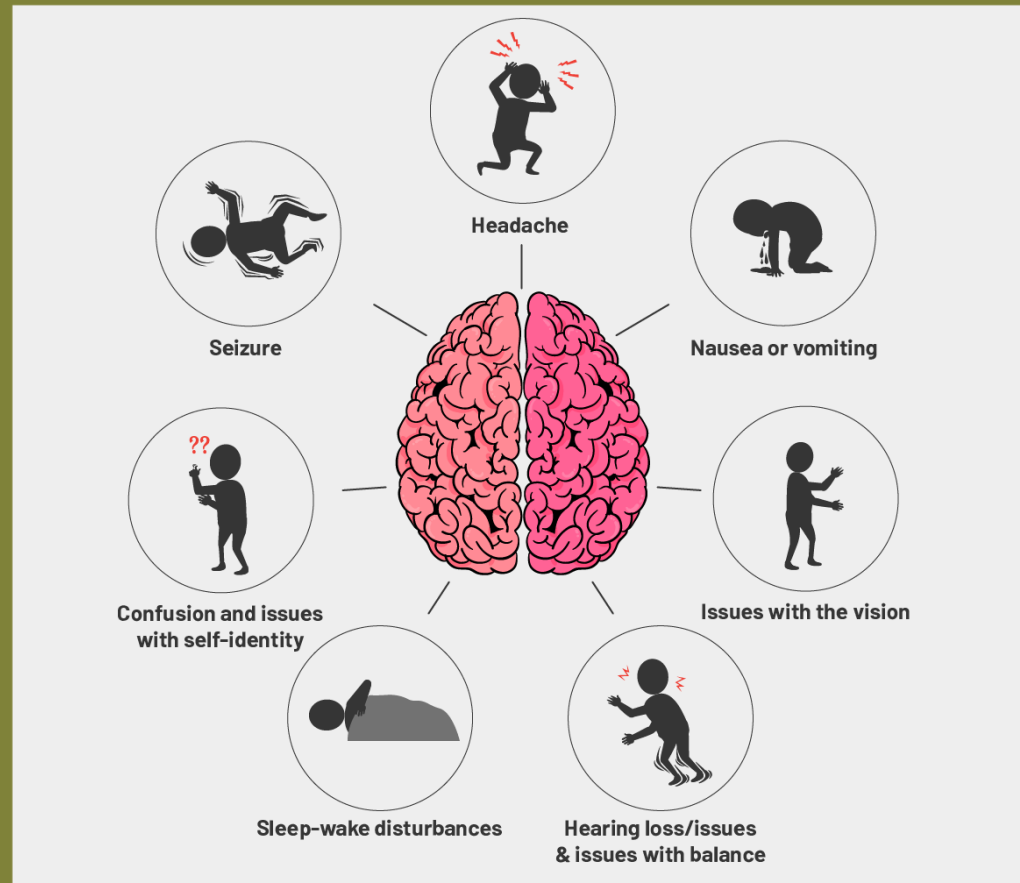
# Due to its complexity, childhood cancer is best managed on a clinical trial



# While there are no screening tests recommended for brain cancers, please see a Medical Professional for these symptoms

**Subjective**  
Appetite  
Balance  
Motor/Sensory

**Objective**  
Weight  
Eye exam  
Neurological testing




**KNOW THE 10 COMMON SYMPTOMS OF BRAIN CANCER**



## Being Mindful of Brain Cancer Symptoms

These noticeable symptoms could be a sign of brain cancer.



See your doctor if you experience these signs or symptoms.



[moffitt.org/take-charge](http://moffitt.org/take-charge)

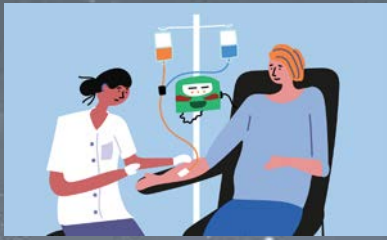© 2017 Moffitt Cancer Center

Source: Moffitt Cancer Center

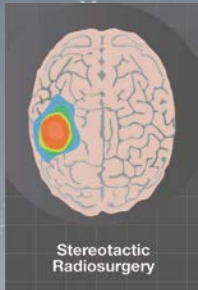

# In summary, brain cancer is best managed with targeted treatment that improves outcomes and minimizes side effects

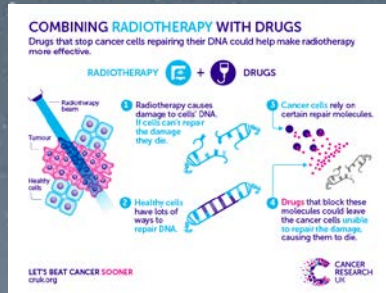## Aim More



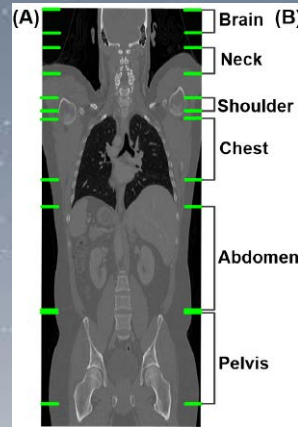
Molecular/Genetic targeting



Smaller targets  
UNIVERSITY OF HAWAII  
CANCER CENTER  
50 Years of Progress

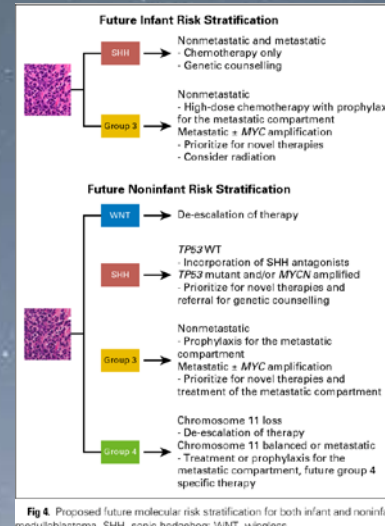


Radiation sensitizers

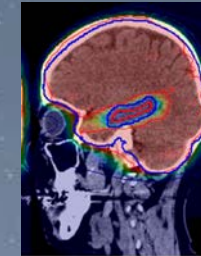


Better imaging

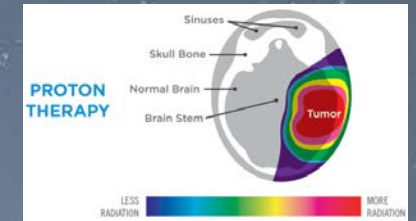
## Shoot Less



Risk groups



Organ sparing



Protons

# References

- Title (Slide 1)

[www.smithsonianmag.com](http://www.smithsonianmag.com)

- Slide 2

<https://immunizebc.ca/sites/default/files/photos/istock-664074494.jpg>

[https://images.indianexpress.com/2020/02/nature\\_happiness\\_759.jpg](https://images.indianexpress.com/2020/02/nature_happiness_759.jpg)

<https://cdn.searchenginejournal.com/wp-content/uploads/2020/07/5-practical-tips-to-step-up-your-audience-targeting-game-5efc892608996-1520x800.png>

<https://s4be.cochrane.org/app/uploads/2013/04/screening-people.jpg>

- Slide 3

<https://ana-neurosurgery.com/biden-brain-cancer/>

<https://www.mountsinai.org/about/newsroom/2015/the-facts-about-beau-bidens-cancer>

[https://www.biography.com/.image/ar\\_1:1%2Cc\\_fill%2Ccs\\_srgb%2Cfl\\_progressive%2Cq\\_auto:good%2Cw\\_1200/MTC1NzQ5ODk4ODEyMDA3NDc5/joe-and-beau-biden-gettyimages-94899242.jpg](https://www.biography.com/.image/ar_1:1%2Cc_fill%2Ccs_srgb%2Cfl_progressive%2Cq_auto:good%2Cw_1200/MTC1NzQ5ODk4ODEyMDA3NDc5/joe-and-beau-biden-gettyimages-94899242.jpg)

- Slide 4

<https://www.linbioscience.com/Pipeline/LBS002>

- Slide 5

<https://www.researchgate.net/profile/Synho-Do/publication/284219019/figure/fig1/AS:298940898529283@1448284472286/A-Images-of-whole-body-CT-scan-and-region-of-each-body-part-B-examples-of.png>

<https://www.cancertodaymag.org/PublishingImages/issues/2019-2020%20Winter/3-early-chemotherapy-dose-reductions-1500-WEB.jpg>

- Slide 6

<https://www.nm.org/-/media/northwestern/images/care-areas/neurosciences/northwestern-medicine-neurosurgery-header-image.jpg?h=400&w=600&la=en&hash=20D71F4A573695AF395A1C18DF2B6197>

<https://www.cancertodaymag.org/PublishingImages/issues/2019-2020%20Winter/3-early-chemotherapy-dose-reductions-1500-WEB.jpg>

[https://www.itnonline.com/sites/default/files/styles/content\\_large/public/BrainLungCancerMetastasesRadiosurgeryColoradoStudy.jpg?itok=As5JCUKv](https://www.itnonline.com/sites/default/files/styles/content_large/public/BrainLungCancerMetastasesRadiosurgeryColoradoStudy.jpg?itok=As5JCUKv)

[https://www.pulmonaryfibrosis360.com/us/sites/default/files/simple\\_image/holistic-care-diagram.png](https://www.pulmonaryfibrosis360.com/us/sites/default/files/simple_image/holistic-care-diagram.png)

- Slide 7

<https://www2.lbl.gov/images/MicroWorlds/EMSpec.gif>

- Slide 8

<https://zniup3zx6moydqfpv9y6sgtf-wpengine.netdna-ssl.com/wp-content/uploads/2018/01/180105-Radiotherapy-and-drugs-blog.png>

- Slide 9

[https://www.brainlab.org/wp-content/uploads/2017/08/BrainlabOrg\\_Illustrations\\_BDR\\_16DEC15\\_Page\\_25.jpg](https://www.brainlab.org/wp-content/uploads/2017/08/BrainlabOrg_Illustrations_BDR_16DEC15_Page_25.jpg)

- Slide 10

[https://www.verywellmind.com/thmb/m4oICAW6AM8f6ghRLC8MkDyYiqM=/1500x844/smart/filters:no\\_upscale\(\)/hippocampus\\_brain-5783df885f9b5831b5cee889.jpg](https://www.verywellmind.com/thmb/m4oICAW6AM8f6ghRLC8MkDyYiqM=/1500x844/smart/filters:no_upscale()/hippocampus_brain-5783df885f9b5831b5cee889.jpg)

<https://d3j71xaburhd42.cloudfront.net/age8bce1e1a8aee31fbbef5672c580b3d3fdef54/3-Figure3-1.png>

# References, continued

- Slide 11

[https://pubs.rsc.org/image/article/2015/mb/c5mb00278h/c5mb00278h-f1\\_hi-res.gif](https://pubs.rsc.org/image/article/2015/mb/c5mb00278h/c5mb00278h-f1_hi-res.gif)

[https://www.mdpi.com/cancers/cancers-11-01616/article\\_deploy/html/images/cancers-11-01616-g001.png](https://www.mdpi.com/cancers/cancers-11-01616/article_deploy/html/images/cancers-11-01616-g001.png)

- Slide 12

<https://thejns.org/pediatrics/view/journals/j-neurosurg-pediatr/23/3/full-2018.10.PEDS18377f3.jpg>

<https://thejns.org/pediatrics/view/journals/j-neurosurg-pediatr/23/3/article-p261.xml>

- Slide 13

<https://www.cancer.gov/rare-brain-spine-tumor/tumors/medulloblastoma>

- Slide 14

Northcutt *et al.* Medulloblastoma. *Nat Rev Dis Prim* 5:Article 11 (2019).

Ramaswamy and Taylor. Medulloblastoma: From Myth to Molecular. *J Clin Onc* 35(21):2355-63 (2017).

- Slide 15

<https://www.nm.org/-/media/northwestern/images/care-areas/neurosciences/northwestern-medicine-neurosurgery-header-image.jpg?h=400&w=600&la=en&hash=20D71F4A573695AF395A1C18DF2B6197>

<https://www.cancertodaymag.org/PublishingImages/issues/2019-2020%20Winter/3-early-chemotherapy-dose-reductions-1500-WEB.jpg>

[https://www.itnonline.com/sites/default/files/styles/content\\_large/public/BrainLungCancerMetastasesRadiosurgeryColoradoStudy.jpg?itok=As5JCUKv](https://www.itnonline.com/sites/default/files/styles/content_large/public/BrainLungCancerMetastasesRadiosurgeryColoradoStudy.jpg?itok=As5JCUKv)

- Slide 16

<https://provisionhealthcare.com/wp-content/uploads/2018/10/brain-comparison-slider-protontherapy.png>

MacEwan *et al.* Effects of vertebral-body-sparing proton craniospinal irradiation on the spine of young pediatric patients with medulloblastoma. *Adv Rad Onc* 2(2): P220-7 (2017).

- Slide 17

<https://i.ibb.co/k46pCj6/clinical-trials-process.png>

[http://www.survivorshipguidelines.org/pdf/2018/COG\\_LTFU\\_Guidelines\\_v5.pdf](http://www.survivorshipguidelines.org/pdf/2018/COG_LTFU_Guidelines_v5.pdf)

- Slide 18

[https://cytecare.com/wp-content/uploads/2019/08/Brain-Cancer-Grey-Matters\\_621.png](https://cytecare.com/wp-content/uploads/2019/08/Brain-Cancer-Grey-Matters_621.png)

<https://moffitt.org/media/6327/brain-cancer-infographic.jpg>

- Slide 19: Material cited in previous slides

- Post: Metastatic brain tumors

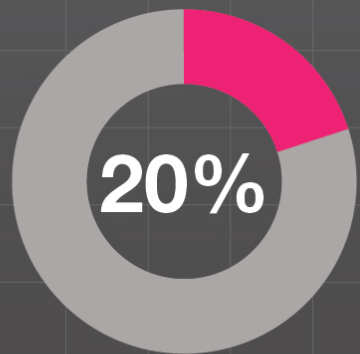
[https://www.brainlab.org/wp-content/uploads/2017/08/BrainlabOrg\\_Illustrations\\_BDR\\_21JUL16-37.jpg](https://www.brainlab.org/wp-content/uploads/2017/08/BrainlabOrg_Illustrations_BDR_21JUL16-37.jpg)

- Post: Medulloblastoma genetic groups

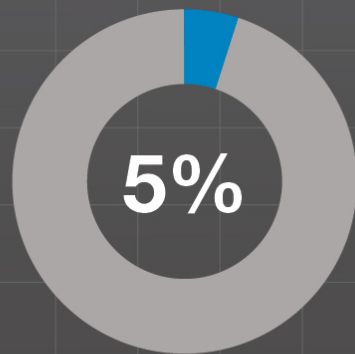
<https://thejns.org/pediatrics/view/journals/j-neurosurg-pediatr/23/3/article-p261.xml>

# Metastatic brain tumors most often come from the lung, breast, skin, kidney, and GI tract

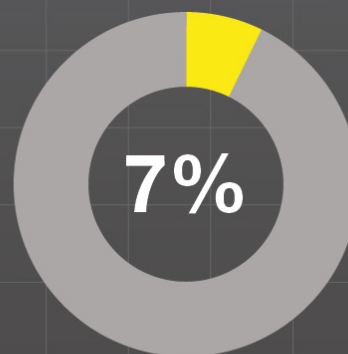
Most Common Primary Tumors and Their Associated Brain Metastases Incidence Proportions\*



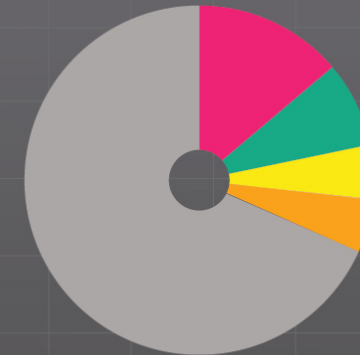
Lung



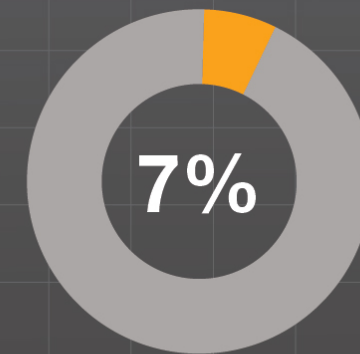
Breast



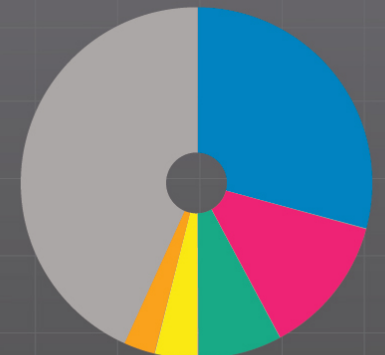
Melanoma



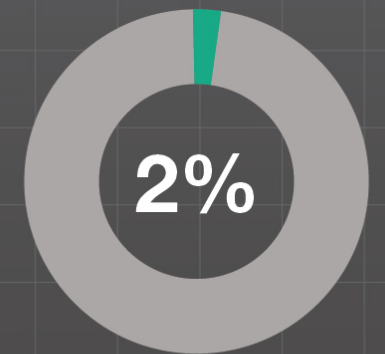
Male



Renal



Female



Colorectal

# Medulloblastoma can be separated into groups based on the driver (activating) gene

Subgroup	WNT		SHH				Group 3			Group 4		
Incidence	10%		30%				25%			35%		
Subtype	WNT α	WNT β	SHH α	SHH β	SHH γ	SHH δ	Group 3α	Group 3β	Group 3γ	Group 4α	Group 4β	Group 4γ
Gender	♂ = ♀		♂ = ♀				♂♂ = ♀			♂♂♂ = ♀		
Subtype proportion												
Age	3-17	>10	3-17	0-3	0-3	>17	0-10	3-17	0-10	3-17	3-17	3-17
Metastases	9%	21%	20%	33%	9%	9%	43%	20%	40%	40%	40%	40%
5 year survival	97%	100%	70%	70%	90%	90%	65%	55%	40%	65%	75%	80%
Copy Number Changes	6-		<i>MYCN</i> amp, <i>GLI2</i> amp, <i>YAP1</i> amp	<i>PTEN</i> Loss	Balanced genome	10q22-11q23.3-	7*, 8-, 10-11-, i17q	<i>OTX2</i> gain, <i>DDX3</i> loss	<i>MYC</i> amp	<i>MYCN</i> amp, <i>CDK6</i> amp	<i>SNCAIP</i> dup	<i>CDK6</i> amp
Other events			<i>TP53</i> mutations			<i>TERT</i> promotor mutations		High <i>GF11/1B</i> expression				
Histology	Classic, LCA(rare)		Desmoplastic, Nodular Classic, LCA				Classic, LCA			Classic, LCA		

